

Clinical evaluation of CT scans: Recognition and escalation of incidental findings suspicious of Covid-19 infection

Radiographers are often the first healthcare professional to see a diagnostic image. Preliminary clinical evaluation and escalation to a reporting radiologist will play a key role in early patient diagnosis, infection control and prevention of the deteriorating patient.

All patients who attend for a diagnostic CT scan that includes the thorax and base of lungs and all patients on treatment for breast cancer, lung and mediastinal cancer, oesophago-gastric, liver and pancreatic cancers who receive CBCTs during treatment (or on MRL), will be informed at CT consent or prior to fraction 1 of radiotherapy, that incidental findings suggestive of Covid-19 infection may be found on lungs/lung bases and appropriate steps will be taken as follows.

The aim of this document is to aid us as a team to identify changes in the lungs that should be escalated during the covid-19 epidemic, we request that all CT radiographers review the lungs of all scans, including lung bases on abdominal scans; images should be reviewed in lung windows.

When reviewing the images radiographers should look for characteristic appearances: peripheral or patchy ground glass opacification (see examples in below). If these appearances are seen the radiographer must consult a radiologist while the patient is still on the scanner.

In case where Covid-19 is suspected the following must be done:

- The patient's oxygen levels must be taken, these readings should be reported to the radiologist. If a radiologist is unavailable and the reading is **93% or below** (patient **baseline sats >95%**) then the patient should be discussed with the referring clinician and considered for hospital assessment via the local acute admission pathway, for further monitoring.
- If oxygen levels are normal and radiologist reports the scan as suspicious or definitive for Covid-19, patients should be sent home and be told to self-isolate for 7 days, the referrer and PHE will be informed. If available, patient will have an antibody finger-prick test in the centre before they go home and a swab testing kit will be sent to them at home as well. The results of the tests will advise further patient management, according to the GenesisCare testing protocol.

- The patient must be provided with a mask.
- The scanner and room must be deep cleaned.
- No further patients can be scanned until one hour after the deep clean is finished.
- The multidisciplinary team will determine whether patient proceeds to treatment or is delayed as described below.

Details of the cleaning procedures will be circulated separately along with decontamination processes for all imaging equipment (CT and MRI gantries, ultrasound probes). Please ensure you read and implement.

Dosimetrist / Physicist guidance

Members of the dosimetry and physics team are in a position where they can to assess patient's lungs from the CT planning scans that are carried out on our patients. It is essential that we try to avoid commencing treatment for non CAT1 patients if they have Covid-19.

Patients who have lungs within their CT planning scans should be reviewed by a dosimetrist or physicist at the ROI/Flds stage, using the examples within this document. The CT window level should be set to lung and the images reviewed thoroughly.

If a member of the team suspects that there is evidence of Covid-19 lung changes they should escalate this to another member of the Physics team to review with them. If both parties agree that there are noticeable appearances, then the referring doctor must be contacted immediately and a radiologist should report the scan as soon as possible and ideally, whilst patient is still in the scanner. The radiographers who carried out the CT planning scan should also be notified that Covid-19 is suspected, and a comment written on the pre-treatment Navigator space.

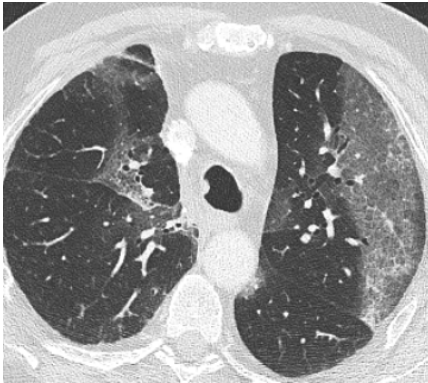The role of the Multidisciplinary Team

If the radiologist reports the scan as suspicious or definitive for covid-19, there is discussion to be held with the multidisciplinary team, consisting of the referring clinician, the centre leader, the lead radiographer, the radiologist and the CMO regarding options of 1/ testing the patient with swab PCR kit sent to them at home ± antibody test and 2/ Deferring patient for 7 days or proceeding to treatment. The referring consultant may opt to delay the patients start date and call the patient directly to discuss. This process may be done by a member of the therapy radiographer team from that Centre if the doctor is unable to contact the patient themselves.

Examples:

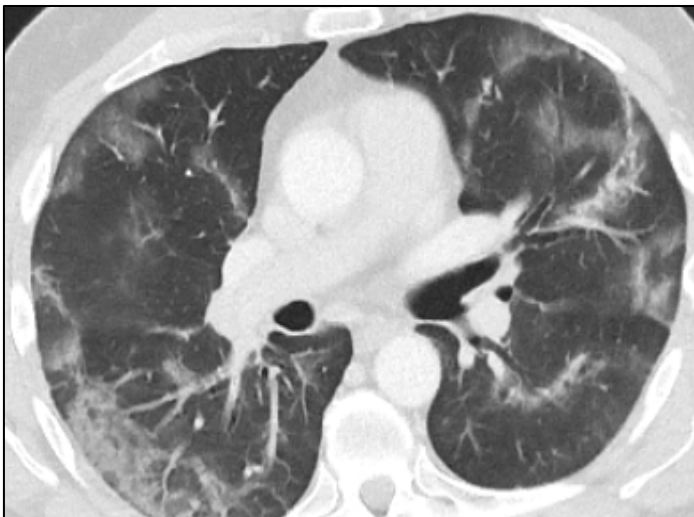
Below is a selection of images that demonstrate the infection:

A.



A. Bilateral ground-glass opacification. You may encounter this on a lung CT, but also a CT of the thoracic spine or cervical spine

B.



B. Peripheral ground-glass opacity (this is an organising pneumonia pattern)

C.

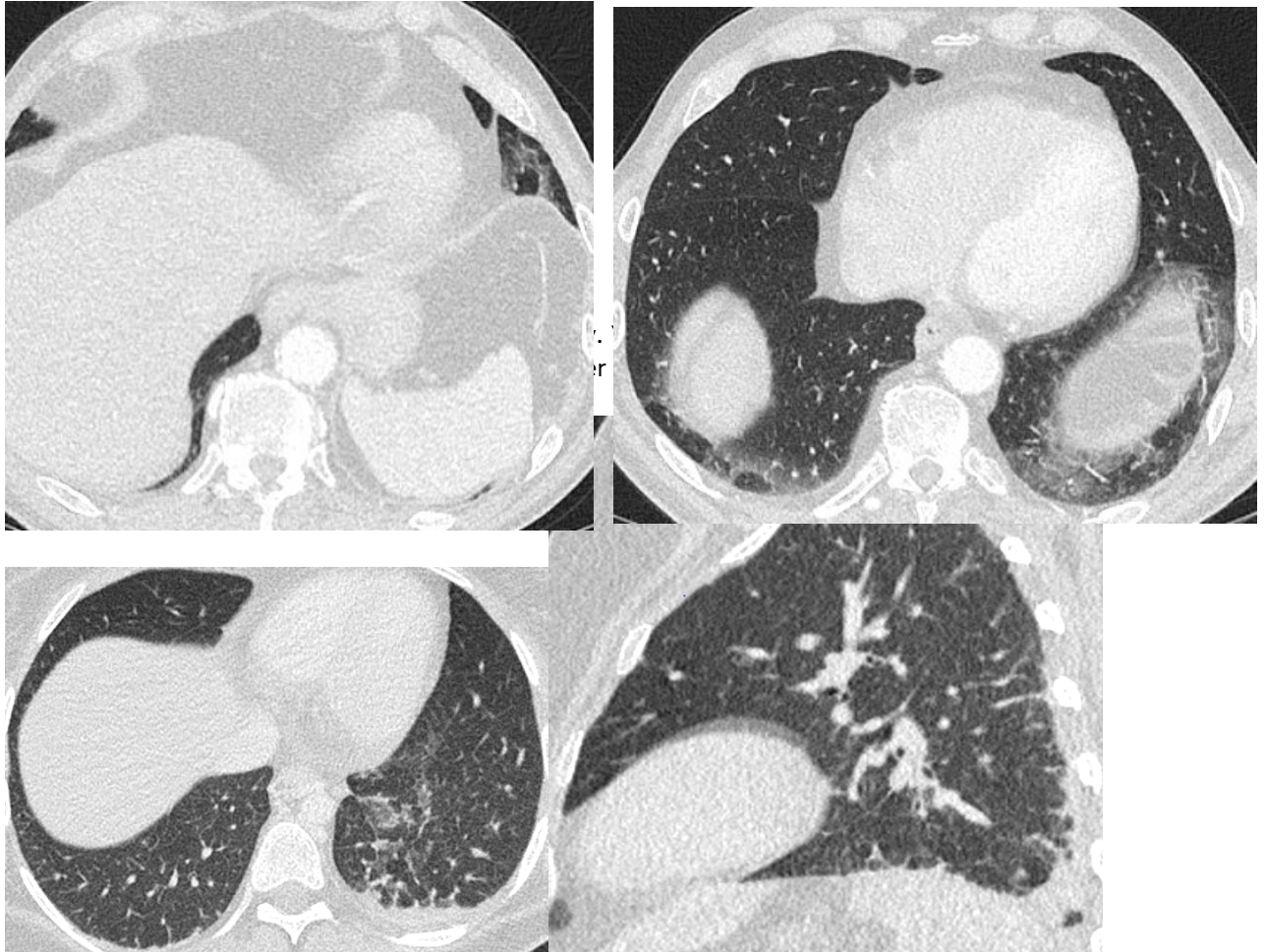


Figure 4. Bi-basal atelectasis which is denser. This too is a non-COVID appearance, but we would want this to be flagged so we can review it.