

Case study:

Wide-field cancerisation, scalp

Presented by: **Dr Eugene Leong** MBBS, FRANZCR

Summary of diagnosis

76-year old man with several biopsy proven SCCs to his scalp.

History

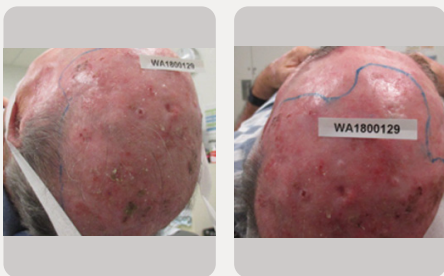
Previous skin cancer treatments: vertex scalp excision for an SCC; right forehead curettage for an SCC. Triple bypass in 2016 and has T2DM, medications include atenolol, telmisartan, aspirin and gliclazide. Patient had a previous post-operative infection and wanted to avoid surgery.

Treatment

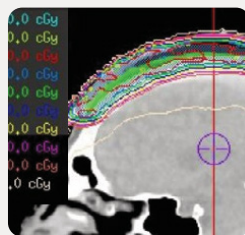
Volumetric modulated arc therapy (VMAT), 60 Gy in 30 fractions for wide field cancerisation

- **9 fractions:** QV cream for mild erythema
- **14 fractions:** G1 erythema on scalp. Soft white paraffin applied to area
- **18 fractions:** G2 skin reaction and multiple scabs on scalp
- **22 fractions:** G2 stable reaction
- **27 fractions:** G2 stable reaction, continuing soft white paraffin
- **End of treatment review:** saline soaks and liquid paraffin BD for 2 weeks
- **9 weeks post end of treatment review:** a new left temple lesion, outside the radiation field biopsied by the referring clinician, confirmed in-situ SCC
- **12 week review:** Skin is smooth and clear; left temple lesion comes and goes and looks less significant; routine review in 6 months

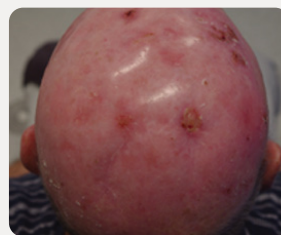Pre-treatment



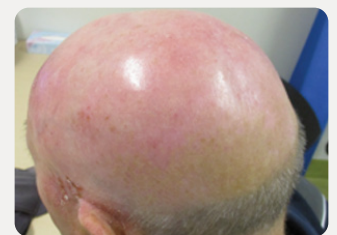Radiation therapy treatment plan



End of treatment review



12 weeks post end of treatment review



Discussion

In cases where conventional therapies such as topicals (eg. 5-Fu, Imiquimod), cryotherapy, curettage and desiccation, and/or photodynamic therapy have failed radiation therapy (RT) may offer an effective nonsurgical option.¹ The use of RT to focally treat BCCs and SCCs is well established and confers cure rates between 79% and 100%, depending on course, location and tumour type.¹⁻⁴ Wide-field volumetric modulated arc therapy (VMAT) is an advanced RT modality that can treat large, curved areas with greater accuracy, and homogeneity than that of existing RT modalities.⁴

Although not always necessary, VMAT can be planned to maximise dosage to affected areas whilst sparing sensitive structures, such as the brain when treating the scalp.⁵ The increased accuracy and precision of VMAT reduces treatment time to 10–15 minutes, thereby making it a fitting option for individuals who are elderly, or have difficulty lying flat for long periods of time.⁴

Patient eligibility/indications^{6,7}

- Keratinocyte cancer:
 - Squamous Cell Carcinoma (SCC)
 - Basal Cell Carcinoma (BCC)
 - Squamous Cell Carcinoma in situ
- Recurrent or high-risk lesions
- Cosmetic concerns
- Widespread lesions

Patient exclusions/considerations^{6,7}

- Prior radiation therapy to site
- Invasion into bone/joints
- Sites with poor vascularity
- Collagen vascular disease
- Sites where radiation therapy would result in unacceptable hair loss
- Naevoid BCC
- Active connective tissue disorders
- Radiation sensitivity
- Inability to lie still for 15 minutes / young age

When to refer to a radiation oncologist



**Extensive Skin Field
Cancerisation (ESFC)**



**Recurrent
lesions**



**Patients who decline or
are unsuitable for surgery**



**Adjuvant to surgery for
high-risk lesions**



**Concerns about cosmetic
outcomes following surgery**



**Failure of other
therapies**



To refer a patient or for more information about our centres and doctors please scan the QR code or go to: genesiscare.com

Contact us

References: 1. Likhacheva A *et al.* Definitive and Postoperative Radiation Therapy for Basal and Squamous Cell Cancers of the Skin: Executive Summary of an American Society for Radiation Oncology Clinical Practice Guideline. *Pract Radiat Oncol* 2020;10(1):8–20 2. Grossi Marconi D, da Costa Resende B, Rauber E, de Cassia Soares P, Fernandes JM Junior, Mehta N, Lopes Carvalho A, Kupelian PA, Chen A. Head and Neck Non-Melanoma Skin Cancer Treated By Superficial X-Ray Therapy: An Analysis of 1021 Cases. *PLoS One*. 2016 Jul 1;11(7):e0156544. 3. Schulte KW, Lippold A, Auras C, Bramkamp G, Breitkopf C, Elsmann HJ, Habenicht EM, Jasnoch V, Müller-Pannas H, Rupperecht R, Suter L. Soft x-ray therapy for cutaneous basal cell and squamous cell carcinomas. *J Am Acad Dermatol*. 2005 Dec;53(6):993–1001. 4. Cho M *et al.* Utility of radiotherapy for treatment of basal cell carcinoma: a review. *Br J Dermatol* 2014;171(5):968–73. 5. Teoh M *et al.* Volumetric modulated arc therapy: a review of current literature and clinical use in practice. *Br J Radiol* 2011 Nov;84(1007):967–96. 6. Cancer Council Australia Keratinocyte Cancers Guideline Working Party. Clinical practice guidelines for keratinocyte cancer. Sydney: Cancer Council Australia. Available from: https://wiki.cancer.org.au/australia/Guidelines:Keratinocyte_carcinoma (accessed January 2026). 7. Gorayski P, Roos D. *AJGP* 2020;49(8):496–499.